



PATIENT

Lucy Munerra

SPECIES

Canine

BREED

Golden retriever

SEX

FS

AGE

11 years

WEIGHT

73 #

INTERPRETED BY

Remo Lobetti, BVSc,
MMedVet (Med),
PhD, Dipl. ECVIM

IMAGING PERFORMED BY

Lara Wiseman, DVM

HOSPITAL NAME

Village Royale Animal
Clinic

REFERRING VET

INVOICE

302673

DATE

12/11/21

PRESENTING CLINICAL SIGNS

History: Suspected mass.

Physical Examination: N/A.

Urinalysis: N/A.

CBC: N/A.

Serum Biochemistry: N/A.

Radiographic Findings: N/A.

ULTRASONOGRAPHIC EXAMINATION OF THE ABDOMEN

Urinary System

Full urinary bladder with a normal appearance and thickness of the wall. Normal anechoic urine with no sediment or uroliths evident.

Normal trigone area, proximal urethra (0.21 cm), and iliac blood vessels.

Normal iliac lymph nodes. Ureters not visualized.

Normal renal size (left 6.7 cm, right 7.2 cm), echogenic appearance, cortico-medullary differentiation, capsule, and pelvis.

Reproductive System

N/A.

Adrenal Glands

Normal shape, echogenic appearance, size, and position. Left 0.52 cm, right 0.6 cm.

Spleen

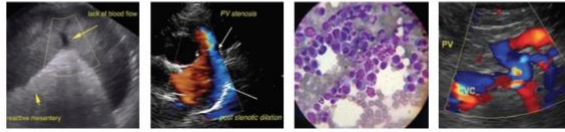
Large irregular mottled echogenic cavitary mass (12.4 x 11.6 cm) obliterating the spleen.

Liver

Enlarged with rounded edges, diffuse mottled echogenic appearance, and loss of portal markings. Multiple irregular parenchymal nodules/masses of varying echogenic appearance (from hypoechogenic to mottled echogenic) and sizes. Small gall bladder containing normal anechoic bile. Normal thickness and appearance of the gall bladder wall. Normal bile duct.

Gastrointestinal

Normal appearance of the stomach, duodenum, small intestine, ileo-cecal junction, and colon with no loss of layering, normal wall thickness (duodenum 0.34 cm) and peristalsis, and no distension of the lumen.



PATIENT

Lucy Munerra

SPECIES

Canine

BREED

Golden retriever

SEX

FS

AGE

11 years

WEIGHT

73 #

INTERPRETED BY

Remo Lobetti, BVSc,
MMedVet (Med),
PhD, Dipl. ECVIM

**IMAGING
PERFORMED BY**

Lara Wiseman, DVM

HOSPITAL NAME

Village Royale Animal
Clinic

REFERRING VET

INVOICE

302673

DATE

12/11/21

Pancreas

Normal size and echogenic appearance. Regular capsule. Normal echogenic appearance of the mesentery and fat surrounding the pancreas.

Free Abdomen

No mesenteric lymphadenomegaly.

Small amount of ascites.

Hyperechogenic appearance of the mesentery.

ULTRASONOGRAPHIC FINDINGS

Primary findings:

- Splenic mass.
- Hepatic nodules/masses.
- Ascites.
- Mesenteric inflammation.

Secondary findings:

- None.

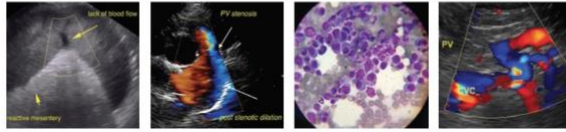
INTERPRETATION OF THE FINDINGS & FURTHER RECOMMENDATIONS

The appearance of the spleen and liver is consistent with metastatic neoplasia and most likely hemangiosarcoma.

The ascites and mesenteric inflammation can be ascribed to the metastatic disease.

Further assessment that could be considered would be 3-view thoracic radiographs and FNA cytology of the splenic and hepatic masses.

As there is metastatic disease, palliative rather than specific therapy would be indicated for this patient.



PATIENT

Lucy Munerra

SPECIES

Canine

BREED

Golden retriever

SEX

FS

AGE

11 years

WEIGHT

73 #

IMAGES

Liver

INTERPRETED BY

Remo Lobetti, BVSc,
 MMedVet (Med),
 PhD, Dipl. ECVIM

IMAGING PERFORMED BY

Lara Wiseman, DVM

HOSPITAL NAME

Village Royale Animal
 Clinic

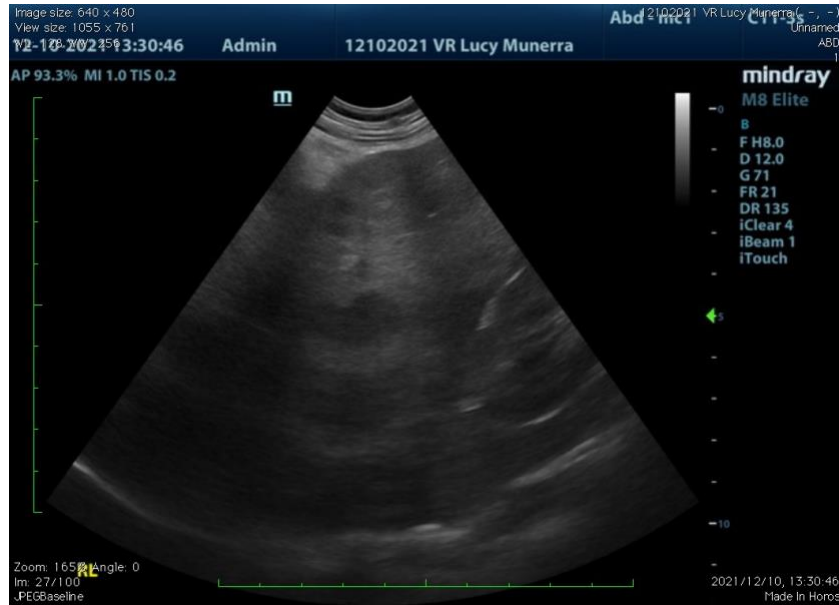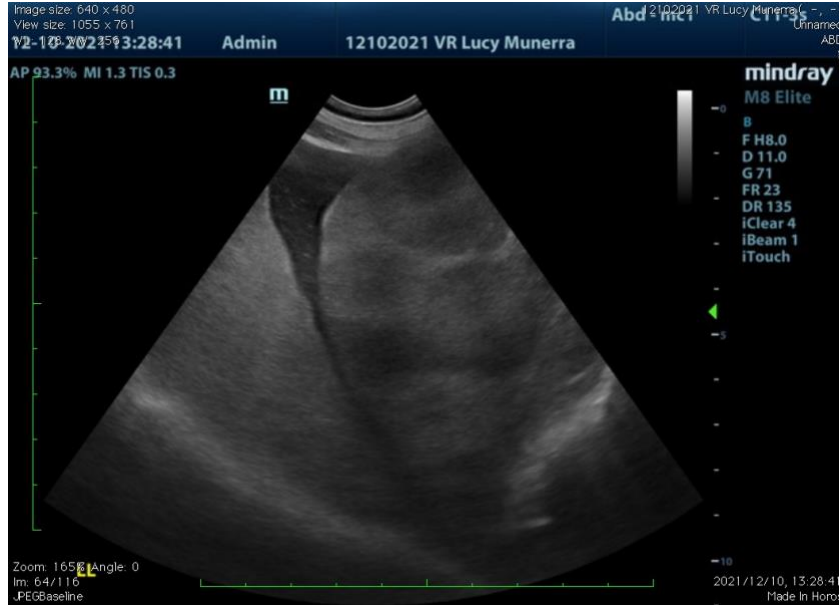REFERRING VET

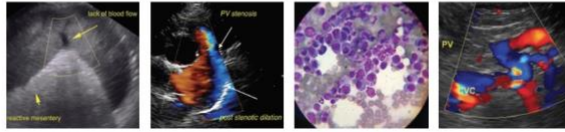
INVOICE

302673

DATE

12/11/21





PATIENT

Lucy Munerra

SPECIES

Canine

BREED

Golden retriever

SEX

FS

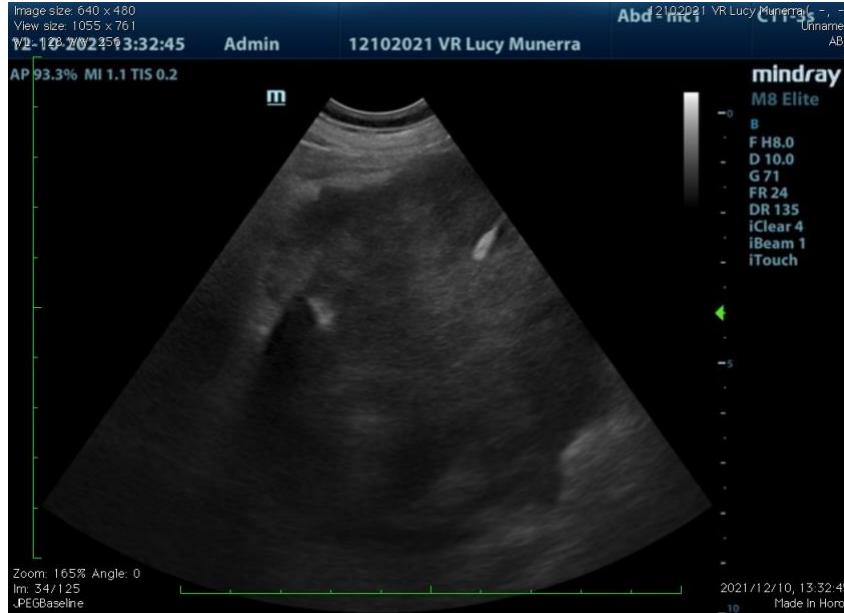AGE

11 years

WEIGHT

73 #

Spleen



INTERPRETED BY

Remo Lobetti, BVSc,
MMedVet (Med),
PhD, Dipl. ECVIM

The information and recommendations provided are based on the images presented by the referring veterinarian. No evaluation can be communicated regarding pathology that was not visible in the image/video clips provided.

IMAGING PERFORMED BY

Lara Wiseman, DVM

Thank you for this referral. If the clinical or image interpretation does not parallel your findings or if I can be of any further assistance please contact me.

Remo Lobetti, BVSc, MMedVet (Med), PhD, Dipl. ECVIM (Internal Medicine)
rlobetti@mweb.co.za

HOSPITAL NAME

Village Royale Animal
Clinic

REFERRING VET

INVOICE

302673

DATE

12/11/21